

---

# Effectiveness of small-volume, intralesional, delayed-release triamcinolone injections in orofacial granulomatosis: A pilot study

M. D. Mignogna, MD, DDS,<sup>a</sup> S. Fedele, DDS,<sup>a</sup> L. Lo Russo, DDS,<sup>a</sup> D. Adamo, DDS,<sup>a</sup>  
and R. A. Satriano, MD<sup>b</sup>  
*Naples, Italy*

**Background:** Orofacial granulomatosis (OFG) is an idiopathic disorder characterized by chronic orofacial swellings causing significant cosmetic and functional problems. Treatment with high-volume triamcinolone injections has been shown to be effective but requires nerve block anesthesia and causes a dramatic temporary increase of lip swelling.

**Objective:** We have performed a noncomparative open-label pilot study in 7 patients with OFG in order to evaluate the effectiveness of small volumes of extended-release high-concentrate triamcinolone injections in reducing lip swelling and preventing recurrences.

**Methods:** Seven patients with OFG were studied. Small-volume, intralesional, high-concentrate, extended-release triamcinolone was injected on the basis of a weekly schedule. A standard cycle consisted of 2 or 3 injection sessions over 14 or 21 days, depending on the clinical response.

**Results:** After cycle completion, all patients remained without recurrences or with cosmetically acceptable slight lip enlargement for a mean time of 19 months (range, 8-30 months). No side effects were observed, except in one patient with hypopigmentation of the skin of the upper lip.

**Conclusions:** Slow-volume, intralesional, high-concentrate, extended-release triamcinolone injections appear to be effective in reducing lip enlargement in patients with OFG and do not require nerve block anesthesia or cause a temporary troublesome increase of swelling. A long disease-free period is generally obtained. (J Am Acad Dermatol 2004;51:265-8.)

Orofacial granulomatosis (OFG) is a descriptive term used for a wide group of granulomatous disorders affecting the soft tissues of the face and oral cavity that are characterized histologically by noncaseating epithelioid granulomas and clinically by recurrent chronic orofacial swelling.<sup>1</sup> Although several areas of the face and oral cavity can be affected,<sup>2,3</sup> the classic and most frequent clinical feature of OFG is a painless, non-

erythematous, nonpruritic edema of the lips (both upper and lower, unilateral and bilateral, symmetric and asymmetric).<sup>4</sup>

After recurrent attacks at irregular intervals, the swelling becomes firm, indurated,<sup>5</sup> and permanent. Thus, it may cause significant cosmetic problems and enormous embarrassment and can interfere with speaking and eating.<sup>2</sup>

Because a clear etiologic factor driving the granulomatous tissue response of OFG has not been identified, rational therapy is not available.<sup>6</sup> Treatment of OFG is aimed at preventing and curing its unsightly sequelae,<sup>7</sup> but if delayed diagnosis occurs, treatment is often unrewarding and burdened by poor outcomes.<sup>8</sup> Corticosteroids have been shown to be effective in reducing facial swelling and preventing recurrences and are considered the (single) most effective drugs in the treatment of OFG.<sup>1,6-8</sup>

Nevertheless, because the chronic course of the disorder requires long-term treatment, the usefulness

---

From the Department of Odontostomatological and Maxillofacial Sciences, Section of Oral Medicine, University of Naples "Federico II,"<sup>a</sup> and the Department of Dermatology, Second University of Naples, Faculty of Medicine.<sup>b</sup>

Funding sources: None.

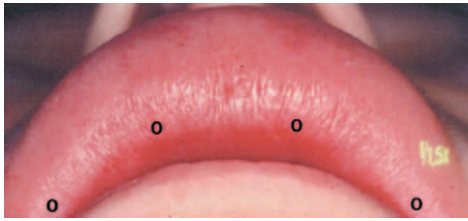
Conflict of interest: None identified.

Reprint requests: Michele D. Mignogna, MD, DDS, Via Domenico Fontana 81, pal. 10, 80128 Naples, Italy. E-mail: [mdmig@tin.it](mailto:mdmig@tin.it) or [mignogna@unina.it](mailto:mignogna@unina.it)

0190-9622/\$30.00

© 2004 by the American Academy of Dermatology, Inc.

doi:10.1016/S0190-9622(03)00769-2



**Fig 1.** Points of needle insertion in a patient with orofacial granulomatosis affecting the whole upper lip.

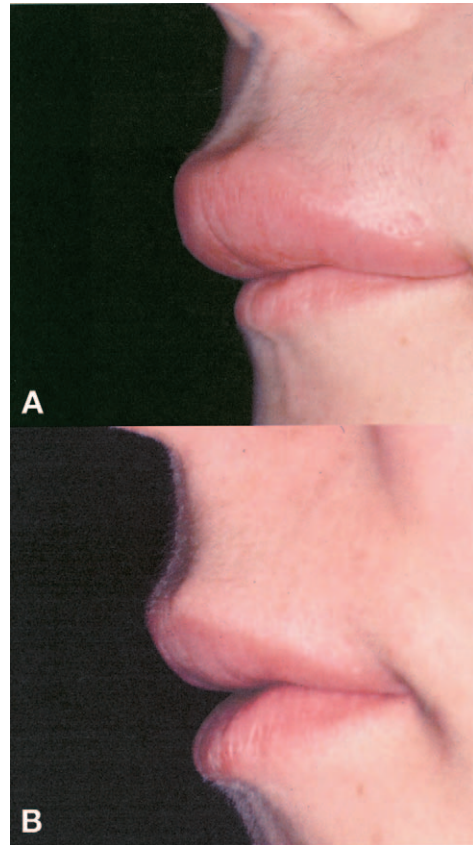
of systemic corticosteroid therapy is limited by its potentially serious side effects. Thus, intralésional injections have been proposed.<sup>9</sup> Initially, triamcinolone acetonide was used in small quantities (0.5-1 mL of 10 mg/mL) so as to avoid patient discomfort, soft tissue atrophy, and hypopigmentation. In fact, these well-known potential side effects of corticosteroid therapy may cause significant cosmetic problems if the lips and perioral area are affected. The clinical response was favorable but temporary, with multiple repeated injections required for months or, in certain cases, years, causing relevant pain and distress in patients.<sup>10,11</sup>

In 1992, Sakuntabhai, MacLeod, and Lawrence<sup>12,13</sup> suggested treating OFG patients with higher volume steroid injections after first numbing the lips by means of mental and infraorbital nerve blocks with 2% lignocaine. In this way, the injections were pain-free and easy to give because the patient was not distressed, and it was possible to inject a high volume of triamcinolone acetonide (10 mg/mL; range, 30-100 mg; mean, 60 mg). Even if lip swelling increases immediately after the injection of such a high volume of drug,<sup>12</sup> this therapy has been shown to be very effective. It has led to almost complete clinical remission and a long-term disease-free period (10-12 months). Side effects have not been seen by the authors.

Because many drugs, including corticosteroids, also currently exist in a delayed-release formulation characterized by a slow extended setting free of the drug, we have treated 7 patients affected by OFG with small quantities of delayed-release high-concentrate triamcinolone.

## PATIENTS AND METHODS

Seven patients (all female; age range, 18-32 years) with OFG were studied. Diagnosis was made performing clinical, hematologic, and histologic investigations in each patient in addition to imaging techniques and radioallergosorbent and patch tests. Thus, we excluded possible local and systemic diseases that can have similar clinical manifestations, including hypersensitivity reactions, acquired and hereditary C<sub>1</sub>INH-related angioedema,



**Fig 2.** Orofacial granulomatosis involvement of the upper lip before (A) and after (B) therapy.

sarcoidosis, tuberculosis, leprosy (Hansen's disease), deep fungal infections, leukemic infiltrate, Crohn's disease, Anderson-Fabry disease, and Ascher's syndrome.

After fulfilling clinical and histopathologic criteria,<sup>1</sup> all patients were given the diagnosis of OFG.

Swelling of the lips was the main clinical feature in all patients; in 3 patients, the lower lip was affected, whereas in the other 4 patients the upper lip was affected. All patients were treated with intralésional corticosteroid injections. We used high concentrations of delayed-release triamcinolone (40 mg/mL), with each injection amounting to 0.1 mL (4 mg).

If the lip was affected by swelling unilaterally, we performed 2 injections, introducing the needle vertically next to the median line and at the corner of the lip (total dose, 0.2 mL [8 mg]). If swelling affected the whole lip, we added two other injections at the opposite side (total dose, 0.4 mL [16 mg]) (Fig 1). The precise point of needle insertion was accurately selected at the virtual line dividing the prolabium and labial mucosa, and the needle was directed deeply toward the oral mucosa with the aim of avoiding atrophy and hypopigmentation of the labial

**Table I.** Clinical data and treatment response of patients with orofacial granulomatosis

	Patient No.						
	1	2	3	4	5	6	7
Sex/Age (y)	M/32	F/25	F/23	F/20	F/21	F/28	F/19
Lip involved	Whole lower	Whole upper	Half lower	Whole upper	Whole upper	Whole upper	Half lower
First cycle (recurrences and injection sessions)	3	3	2	3	3	3	2
Total volume injected [mL (mg)]	1.2 (48)	1.2 (48)	0.4 (16)	1.2 (48)	1.2 (48)	1.2 (48)	0.4 (16)
Disease-free period after first cycle (mo)	10	30	12	8	14	18	16
Further recurrences/injection sessions	1	—	1	1	—	—	1
Follow-up after last injection (mo)	3	30	7	9	14	18	5
Side effects	No	Yes*	No	No	No	No	No

\*Hypopigmentation of the upper lip skin.

skin. Injections were performed with a 1-mL (100 IU) syringe for subcutaneous use.

Therapy was performed on a weekly schedule; a standard cycle consisted of 2 or 3 injection sessions over 14 or 21 days depending on the clinical response (maximum of 3 injections, 0.6-1.2 mL [24-48 mg]). This small volume of corticosteroid injected did not cause significant pain and was generally well tolerated, with very low discomfort. Only two patients reported significant pain at the needle introduction. Thus, they required the application of topical anesthetic gel on the lip a few minutes before the injections.

## RESULTS

After cycle completion, lip swelling started to settle within a few days in all patients, returning to normal size within 2 to 4 weeks (Fig 2). The patients remained without recurrence, or with cosmetically acceptable slight lip enlargement for a mean time of 19 months (range, 8-30 months).

During the cycle, recurrences were usually observed but did not exceed 3 in number. Accordingly, in those patients showing two initial recurrences, a long disease-free period was reached with a cycle of two injection sessions over a period of 2 weeks (0.4-0.8 mL [16-32 mg] depending on the lip area affected). In those showing 3 recurrences, another session was necessary, with a total dose of 0.6 to 1.2 mL (24-48 mg). Subsequent recurrences were observed in 4 patients and treated with a single injection session.

No side effects were observed, with the exception of one patient having hypopigmentation of the

upper lip skin. Clinical data are summarized in Table I.

## DISCUSSION

Permanent facial swelling of OFG may cause significant cosmetic problems and enormous embarrassment and can interfere with speaking and eating. Its early recognition is a key factor in controlling its unsightly sequelae. Patients with long-term, misdiagnosed, nontreated disease present with a firm, indurated, fibrous enlargement of the lips that has no tendency to resolution and generally does not respond well to corticosteroid therapy. In these cases, plastic surgical reduction of the swelling has been suggested<sup>10,14,15</sup> but is probably not warranted or reliably effective.<sup>8</sup> Furthermore, intralesional triamcinolone injections are useful only in reducing further lip enlargement.

On the contrary, if the disease is recognized early, intralesional corticosteroid injections have been shown to be very effective. They reduce acute face swelling and prevent chronic recurrences, obtaining a long disease-free period and representing the cornerstone of OFG therapy.<sup>7,12</sup>

Right now, the best results have been obtained with high-volume intralesional triamcinolone (3-10 mL of 10 mg/mL) injections as proposed by Sakuntabhai, MacLeod, and Lawrence,<sup>13</sup> with a very long disease-free period of about 10 months. However, nerve block anesthesia is necessary to make pain free the infiltration into the lip of such a high volume of steroids. In addition, as a consequence of the high volume injected, the lip swelling was reported to increase to a "dramatic

size<sup>12</sup> in the first 4 to 5 days before starting to subside.

On the contrary, the use of delayed-release high-concentrate triamcinolone (40 mg/mL) as we have described in this study enables us to obtain several advantages.

First, the total volume of triamcinolone is significantly reduced, allowing us to use a 1-mL (100 IU) syringe for subcutaneous infiltration with a small thin needle. This makes the injections relatively painless. For those patients who experience pain and discomfort, however, application of a topical anesthetic gel on the lip a few minutes before the injections is effective in eliminating the pain from needle introduction as we observed in two patients.

In addition, the delayed release of the drug and its high concentration work in synergy, being effective for both resolution of acute swelling and prevention of recurrence for a long period. As we have reported previously, in the course of acute phases, the disease has a high tendency to present recurrences, which are generally controlled with 2 to 3 injection sessions over 2 to 3 weeks. After this cycle, lip size remains stable for a long period even if recurrences are variable and unpredictable.

Our best outcome was obtained in patient 2, with a disease-free period of 30 months. The worst outcome was in patient 4, with the first subsequent recurrence observed 8 months after cycle completion. The observation that both patients were treated with the same dosage of triamcinolone and presented with the same number of recurrences during the first cycle of therapy underscores the high variability and complexity of OFG clinical behavior.

Potential well-recognized side effects of intralesional corticosteroid include skin atrophy and hypopigmentation, the latter of which was observed in only one patient.

In conclusion, small-volume, intralesional, delayed-release, high-concentrate triamcinolone is an effective and relatively painless therapy in patients with OFG. It resolves the acute swelling within 2 to 3 weeks, produces long-term remission, can be easily

repeated in cases of recurrence, and has very few minor side effects.

We thank Mrs Caterina Bonavolontà for providing clinical assistance to patients.

#### REFERENCES

1. Wiesenfeld D, Ferguson MM, Mitchell DN, MacDonald DG, Scully C, Cochran K, et al. Oro-facial granulomatosis: a clinical and pathological analysis. *Q J Med* 1985;54:101-13.
2. Mignogna MD, Fedele S, Lo Russo L, Lo Muzio L. Orofacial granulomatosis with gingival onset. *J Clin Periodontol* 2001;7:692-5.
3. Mazon SD, Rogers RS III. Melkersson-Rosenthal syndrome. *Semin Dermatol* 1995;14:135-9.
4. Zimmer WM, Rogers RS III, Reeve CM, Sheridan PJ. Orofacial manifestations of Melkersson-Rosenthal syndrome: a study of 42 patients and review of 220 cases from the literature. *Oral Surg Oral Med Oral Pathol Oral Radiol Endod* 1992;74:610-9.
5. Ziem PE, Pfrommer C, Goerdts S, Orfanos CE, Blume-Peytavi U. Melkersson-Rosenthal syndrome in childhood: a challenge in differential diagnosis and treatment. *Br J Dermatol* 2000;143:860-3.
6. Rogers RS III. Granulomatous cheilitis, Melkersson-Rosenthal syndrome, and orofacial granulomatosis. *Arch Dermatol* 2000;136:1557-8.
7. Rogers RS III. Melkersson-Rosenthal syndrome, and orofacial granulomatosis. *Dermatol Clin* 1996;14:371-9.
8. Orofacial granulomatosis. [editorial]. *Lancet* 1991;338:20-1.
9. Eisenbud L, Hymowitz S, Shapiro R. Cheilitis granulomatosa: report of a case treated with injection of triamcinolone acetonide aqueous suspension. *Oral Surg* 1971;32:384-9.
10. Krutchkoff D, James R. Cheilitis granulomatosa: successful treatment with combined local triamcinolone injection and surgery. *Arch Dermatol* 1978;114:1203-6.
11. Allen CM, Carnisa C, Hamzeh S, Stephens L. Cheilitis granulomatosa: report of six cases and review of the literature. *J Am Acad Dermatol* 1990;23:444-50.
12. Sakuntabhai A, MacLeod RI, Lawrence CM. Intralesional steroid injection after nerve-block in orofacial granulomatosis. *Lancet* 1992;340:969.
13. Sakuntabhai A, MacLeod RI, Lawrence CM. Intralesional steroid injection after nerve block anesthesia in the treatment of orofacial granulomatosis. *Arch Dermatol* 1993;129:477-80.
14. Glickman LT, Gruss JS, Birt BD, Kohli-Dang N. The surgical management of Melkersson-Rosenthal syndrome. *Plast Reconstr Surg* 1992;89:815-21.
15. Rey R, Carreau JP, Gola R, Berbis P. Syndrome de Melkersson-Rosenthal. Intérêt de la chéiloplastie de réduction. *Ann Dermatol Venerol* 1996;123:325-7.